

Legal Adult Age Estimation By Cameriere's Third Molar Maturity Index In Coastal Andhra Population

**Dr. AJAY BENARJI MDS¹, Dr. TUMMALA ANANYA², Dr. BABBURI SURESH MDS³,
Dr. V APARNA MDS⁴, Dr. ANUSHA VENKATA NAYANALA MDS⁵, Dr. U VIJAYALAKSHMI
MDS⁶, Dr. CHANUMOLU GAYATHRI BDS⁷, Dr. G LAKSHMI GAYATHRI BDS⁸**

¹Professor, Department of Oral pathology. Drs Sudha and Nageswara Rao Siddhartha institute of dental sciences, Gannavaram, Andhra Pradesh.

²PG STUDENT, Department of Oral and Maxillofacial Surgery, Drs Sudha and Nageswara Rao Siddhartha institute of dental sciences, Gannavaram, Andhra Pradesh.

³Professor & HOD, Department of Oral pathology. Drs Sudha and Nageswara Rao Siddhartha institute of dental sciences, Gannavaram, Andhra Pradesh.

⁴Professor, Department of Oral pathology. Drs Sudha and Nageswara Rao Siddhartha institute of dental sciences, Gannavaram, Andhra Pradesh.

⁵Associate professor, Department of Oral Medicine and Radiology. Drs Sudha and Nageswara Rao Siddhartha institute of dental sciences, Gannavaram, Andhra Pradesh.

⁶Associate professor, Department of Oral and Maxillofacial Surgery, Drs Sudha and Nageswara Rao Siddhartha institute of dental sciences, Gannavaram, Andhra Pradesh.

⁷Sibar Dental Care, Dornakal Road, Suryaraopet, Vijayawada, Andhra Pradesh.

⁸Sibar Dental Care, Dornakal Road, Suryaraopet, Vijayawada, Andhra Pradesh.

ABSTRACT

Establishing whether an individual has attained legal adulthood is crucial in forensic, medico-legal, and civil contexts, particularly when valid identity documents are unavailable^{1,2}. Dental age estimation is considered reliable due to the relative resistance of teeth to environmental and systemic influences³. After adolescence, the mandibular third molar is the only tooth undergoing active development, making it a valuable indicator for age estimation around the legal threshold of 18 years^{4,5}. Cameriere's Third Molar Maturity Index (I3M), based on the measurement of open apices relative to tooth length, has been proposed as a reliable method to discriminate between minors and adults⁶. The present cross-sectional study evaluates the applicability of Cameriere's I3M cutoff value (0.08) in a Coastal Andhra population and examines correlations with chronological age, gender differences, and side-wise variation.

INTRODUCTION

Age estimation plays a vital role in forensic identification, legal responsibility, immigration issues, criminal proceedings involving minors, and civil disputes^{1,7}. Chronological age may not always be verifiable due to the absence of valid documentation, necessitating biological age estimation methods². Among skeletal and dental indicators, dental maturation is considered more stable and less influenced by nutrition, disease, and hormonal variations^{3,8}. In individuals above 14 years of age, the completion of second molar root formation limits the usefulness of most teeth, leaving the third molar as the primary dental indicator for age estimation during late adolescence^{4,5}.

Cameriere et al. introduced the Third Molar Maturity Index (I3M), calculated as the ratio of the sum of open apices of the mesial and distal roots to the total tooth length⁶. A cutoff value of I3M < 0.08 has been widely validated across different populations to indicate attainment of 18 years of age^{6,9,12}. However, population-specific validation is essential due to genetic and environmental influences on dental maturation¹³. This study aims to assess the reliability of Cameriere's I3M in a Coastal Andhra population.

AIM AND OBJECTIVES

Aim: To estimate legal adult age using Cameriere's third molar maturity index in the Coastal Andhra population.

Objectives:

1. To correlate chronological age with third molar maturity index (I3M).
2. To assess gender-wise differences in third molar maturation.
3. To compare maturity differences between right and left mandibular third molars.

MATERIALS AND METHODS

A descriptive cross-sectional study was conducted using 250 digital orthopantomographs (OPGs) obtained from the archives of the Department of Oral Medicine and Radiology, Drs. Sudha & Nageswara Rao Siddhartha Institute of Dental Sciences, Gannavaram. The sample comprised 125 males and 125 females aged between 14 and 22 years. Ethical clearance was obtained prior to the study¹⁴.

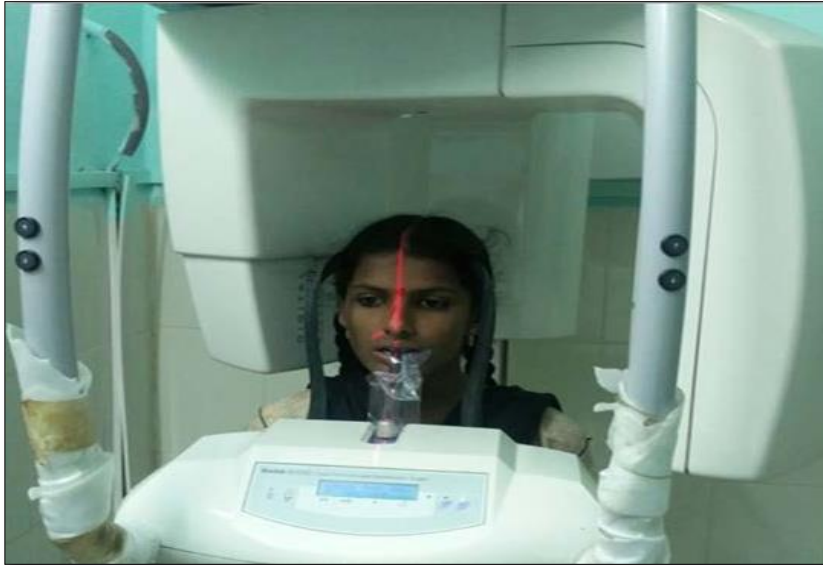

Fig.1: Kodak K-Stream 8000C for OPGs

Inclusion criteria included healthy individuals with fully visible mandibular third molars, adequate radiographic quality, and absence of systemic or local conditions affecting dental development¹⁵.

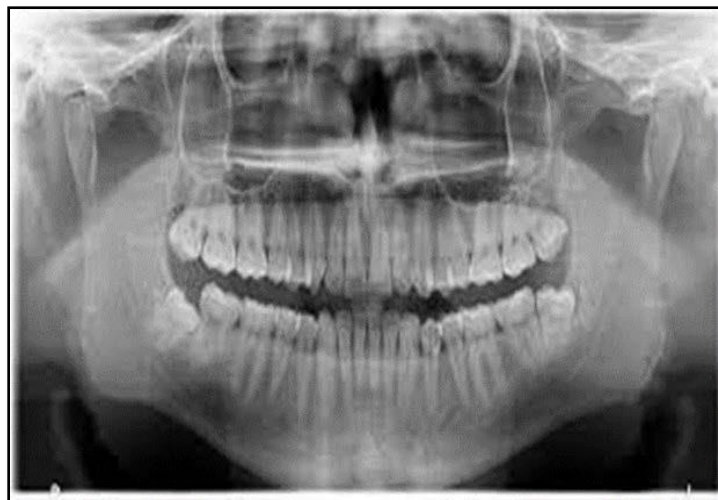


Fig.2: Digital Panoramic Radiograph

Exclusion criteria included individuals above 22 years, those with impacted, grossly carious, restored, or endodontically treated third molars, craniofacial anomalies, facial trauma, or unclear

radiographs¹⁶. Digital OPGs were analyzed using ImageJ software (version 1.52a). The apical widths of mesial (a) and distal (b) roots and the total tooth length (L) were measured. The I3M value was calculated as $(a+b)/L$, and a value of 0.00 was assigned when the apex was completely closed⁶. Measurements were standardized to compensate for magnification errors¹⁷. Data were tabulated in Microsoft Excel and analyzed using SPSS version 21.0.

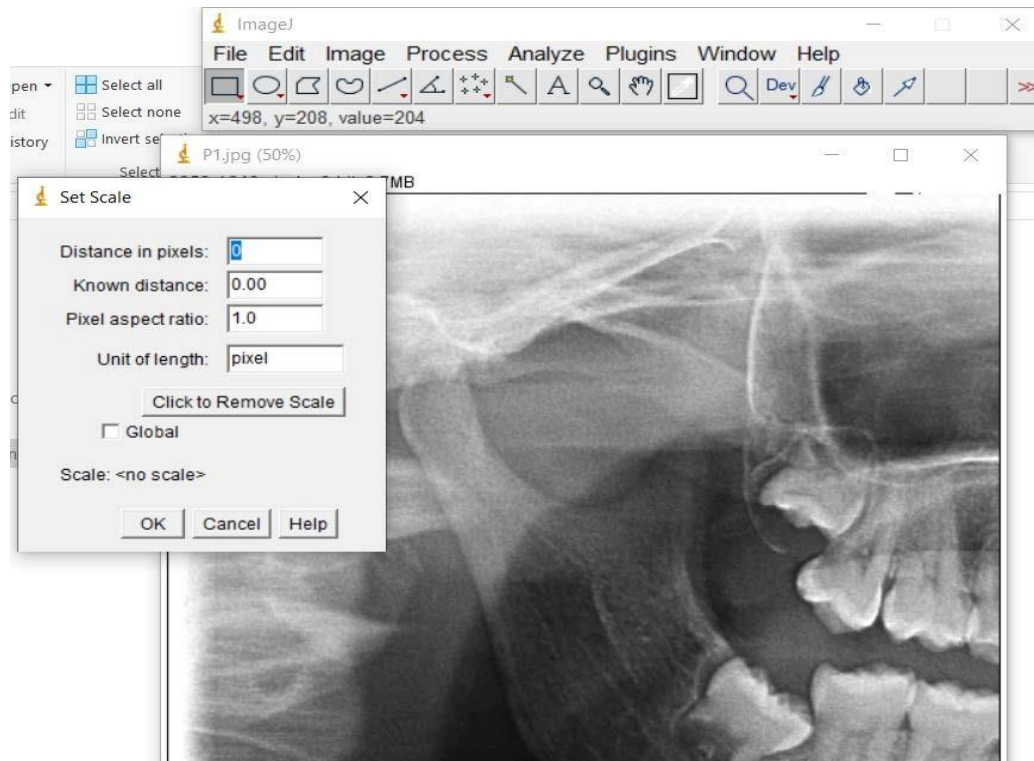


Fig. 3: Image J software

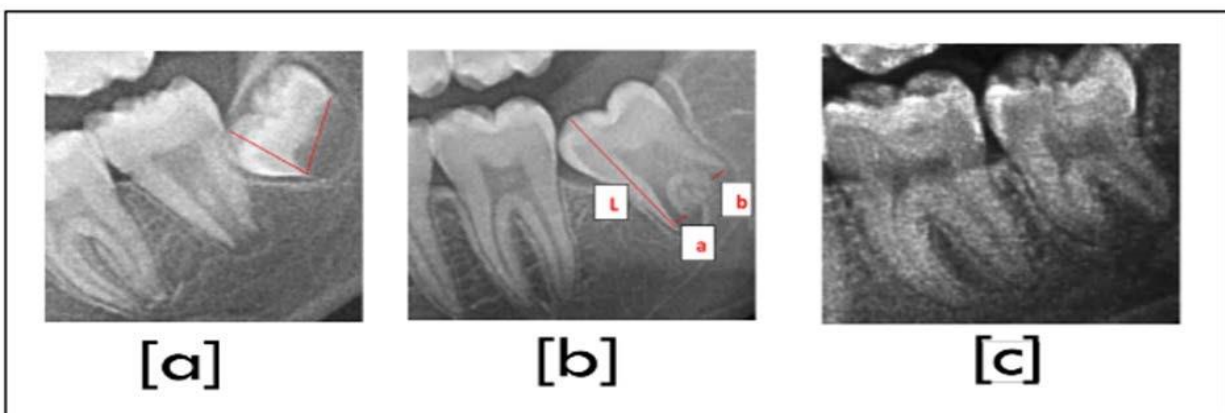


Fig. 4: Example of Cameriere's Method – Measuring of Open apices and length of the tooth.

There are three different categories named a, b, c, as shown in the pictorial representation.

CATEGORY	FEATURES	MEASUREMENT
(a)	When there is no root commencement, and the only crown is formed	<ul style="list-style-type: none"> • Apical root width is measured by drawing a straight line between the inner aspect of mesial and distal borders at its most inferior point. • Total length (TL) is measured from the highest point of the tip of the crown perpendicular to the width along its long axis of the crown.
(b)	When crown and root are formed with open apex	<ul style="list-style-type: none"> • The apical width of mesial and distal roots is measured separately on their inner sides. • TL same as (a) up to the length of root formation
(c)	When crown and root formation are complete with closed apex	<ul style="list-style-type: none"> • Only TL is measured as the apex is closed.

Table:1. Different categories seen in Cameriere’s Method

Statistical analysis included descriptive statistics, independent t-tests for side-wise comparison, and Pearson’s correlation coefficient to assess the relationship between chronological age and I3M values. Statistical significance was set at $p < 0.05$ ¹⁸

RESULTS

The study population showed nearly equal gender distribution across all age groups, with a mean age of 18.09 ± 2.28 years for females and 18.22 ± 2.30 years for males. Independent t-test analysis revealed a statistically significant difference between left and right mandibular third molar maturity indices, with the left side showing slightly higher mean I3M values.

Age groups	Females	Males	Total
14- 14.9	13	17	30
15- 15.9	19	9	28
16- 16.9	15	16	31
17- 17.9	15	16	31
18- 18.9	14	15	29
19- 19.9	15	17	32
20- 20.9	16	18	34
21- 21.9	18	17	35

Table. 2 : Age wise and Gender wise distribution of the Study Population.

A strong negative correlation was observed between chronological age and I3M values for both left ($r = -0.715$, $p < 0.001$) and right ($r = -0.727$, $p < 0.001$) mandibular third molars, indicating a decrease in I3M with increasing age. A strong positive correlation was noted between left and right side I3M values ($r = 0.921$, $p < 0.001$), suggesting symmetrical maturation patterns.

	Side	Mean	Std.Deviation	Std.Error	p value
TMM	38	0.27578	0.391053	0.024732	p<0.058*
	48	0.25739	0.371976	0.023526	

Table 3: Representing Independent t test statistics between left and right side for Third molar maturity index.

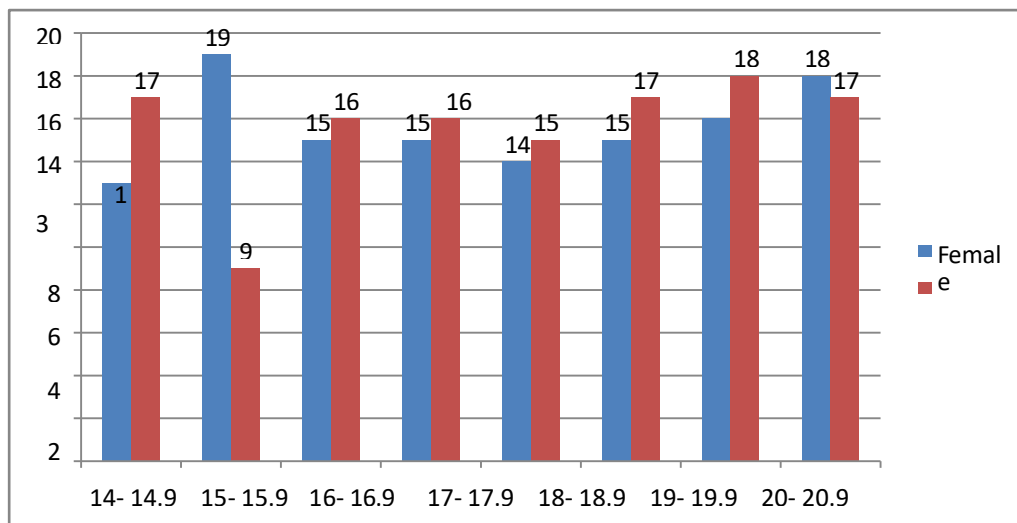
*Statistical significance level set as $p < 0.05$.

	N	Mean	Std. deviation	Correlation	p value
CA	250	18.15	2.29	$r = -0.715^{**}$	$p < 0.001^*$
38 TMM	250	0.27	0.39		

Table 4: Representing the correlation between Chronological Age and left side for third molar maturity index.

*Pearson correlation co-efficient, $r < 0 < 1$.

Gender-wise analysis demonstrated no statistically significant differences in third molar maturation between males and females, although males showed slightly advanced maturation trends in certain I3M classes, consistent with previous studies.



Graph 1: Graphical representation of Age and Gender wise distribution of the study population.

	N	Mean	Std. Deviation	Correlation	p value
CA	250	18.15	2.29	r = -0.727**	p<0.001*
48 TMM	250	0.25	0.37		

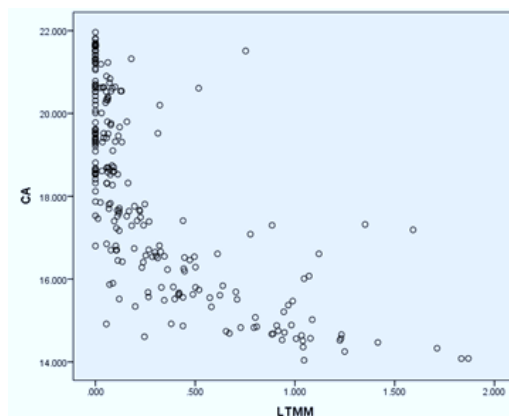
Table 5: Representing the correlation between Chronological Age and left side for third molar maturity index.

* Pearson correlation co-efficient, $r < 0 < 1$.

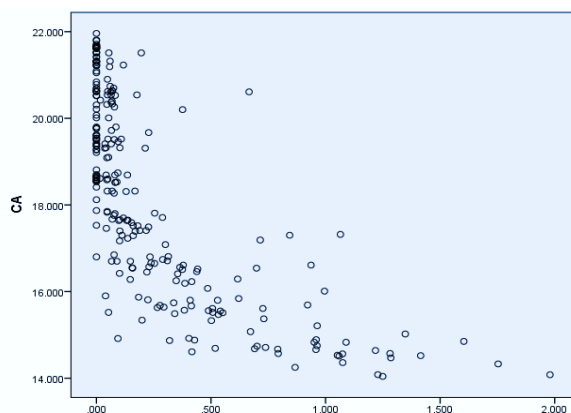
Side	N	Mean	Std. Deviation	Correlation	p value
38 TMM	250	0.27	0.39	r = -0.921**	p<0.001*
48 TMM	250	0.25	0.37		

Table 6: Representing the correlation between two sides for third molar maturity index.

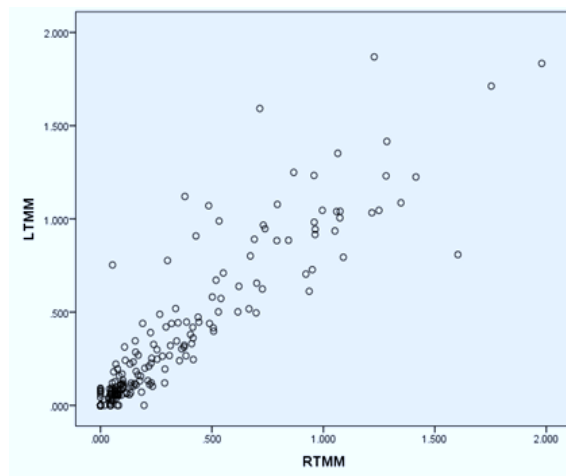
*Pearson correlation co-efficient, $r < 0 < 1$.



Simple scatter plot representing the negative relation between the Chronological Age and left side for third molar maturity index.



Simple scatter plot representing the negative relation between the Chronological Age and right side for third molar maturity index.



Simple scatter plot representing the positive relation between the Left and right side for third molar maturity index.

DISCUSSION

Accurate age estimation around the legal threshold of 18 years is critical, as misclassification may have serious legal and social consequences^{1,2}. Dental age estimation, particularly using third molar development, has gained prominence due to its non-invasive nature and relatively high reliability^{3,5}. The present study supports the validity of Cameriere's I3M method in the Coastal Andhra population.

The strong inverse correlation between chronological age and I3M values observed in this study aligns with findings from European, African, South American, and other Indian populations^{6,9,13}. The absence of significant gender differences is consistent with several previous studies, although minor variations may be attributed to sexual dimorphism and population-specific growth patterns¹⁰⁻¹².

The slight but significant difference between left and right third molars suggests that bilateral assessment enhances accuracy¹⁹.

Receiver operating characteristic (ROC) analysis in comparable studies has demonstrated high sensitivity and specificity for the I3M < 0.08 cutoff, reinforcing its utility as a diagnostic threshold for legal adulthood^{6,11,20}.

Overall, the findings indicate that Cameriere's I3M method is a reliable adjunct for age estimation in forensic and legal practice, especially when used alongside other biological indicators²¹.

CONCLUSION

Cameriere's third molar maturity index demonstrates a strong correlation with chronological age and provides a reliable method for discriminating between minors and adults in the Coastal Andhra population. The cutoff value of I3M < 0.08 can be effectively used to assess legal adult status, with no significant gender bias and high bilateral consistency. Incorporation of this method into routine forensic age estimation protocols may enhance accuracy and objectivity^{6,9,11}.

REFERENCES

1. Thevissen P, Kvaal SI, Dierickx K, Willems G. Ethics in age estimation of unaccompanied minors. *Journal of Forensic Odonto-Stomatology*. 2012;30(1):85-102.
2. Cameriere R, Ferrante L. Canine pulp ratios in estimating pensionable age in subjects with questionable documents of identification. *Forensic science international*. 2011 Mar 20;206(1-3):132-5.
3. Monirifard M, Yaraghi N, Vali A, Vali A, Vali A. Radiographic assessment of third molars development and it's relation to dental and chronological age in an Iranian population. *Dental research journal*. 2015 Jan;12(1):64.
4. Santoro V, De Donno A, Marrone M, Campobasso CP, Introna F. Forensic age estimation of living individuals: A retrospective analysis. *Forensic science international*. 2009 Dec 15;193(1-3):129-e1.
5. Saunders S, DeVito C, Herring A, Southern R, Hoppa R. Accuracy tests of tooth formation age estimations for human skeletal remains. *American journal of physical anthropology*. 1993 Oct;92(2):173-88.
6. de Oliveira FT, Capelozza AL, Lauris JR, de Bullen IR. Mineralization of mandibular third molars can estimate chronological age—Brazilian indices. *Forensic science international*. 2012 Jun 10;219(1-3):147-50.
7. Lizarbe RJ, Adrianzén CS, Quezada-Márquez MM, Galić I, Cameriere R. Demirjian's stages and Cameriere's third molar maturity index to estimate legal adult age in Peruvian population. *Legal Medicine*. 2017 Mar 1;25:59-65.
8. Singh A, Gorea RK, Singla U. Age estimation from the physiological changes of teeth. *Journal of Indian Academy of Forensic Medicine*. 2004;26(3):94-6.
9. Fernandes MM, Tinoco RL, de Braganca DP, de Lima SH, Junior LF, Junior ED. Age estimation by measurements of developing teeth: accuracy of Cameriere's method on a Brazilian sample. *Journal of forensic sciences*. 2011 Nov;56(6):1616-9.
10. Reppien K, Sejrsen B, Lynnerup N. Evaluation of post-mortem estimated dental age versus real age: a retrospective 21-year survey. *Forensic science international*. 2006 May 15;159:S84-8.
11. Solheim T. A new method for dental age estimation in adults. *Forensic science international*. 1993 May 1;59(2):137-47.
12. Baccino E, Tavernier J, Lamendin H, Frammery D, Nossintchouk R, Humbert J. Evaluation of a simple multiple indicator method for age-determination of adult corpses. *medical law legal medicine journal*. 1991 Jan 1; 34 (1): 27-33.
13. Lucy D, Pollard AM, Roberts CA. A comparison of three dental techniques for estimating age at death in humans. *Journal of Archaeological Science*. 1995 May 1;22(3):417-28.
14. Kvaal SI, Kolltveit KM, Thomsen IO, Solheim T. Age estimation of adults from dental radiographs. *Forensic science international*. 1995 Jul 28;74(3):175-85.
15. Stavrianos CH, Mastagas D, Stavrianou I, Karaiskou O. Dental age estimation of adults: A review of methods and principals. *Res J Med Sci*. 2008;2(5):258-68.
16. Priyadarshini C, Puranik Mp, Uma Sr. Dental age estimation methods-a review. *Lap lambert academic publ*; 2015 Apr.
17. Panchbhai AS. Dental radiographic indicators, a key to age estimation. *Dentomaxillofacial Radiology*. 2011 May;40(4):199-212.
18. Massler M, Schour I, Poncher HG. Developmental pattern of the child as reflected in the calcification pattern of the teeth. *American Journal of Diseases of Children*. 1941 Jul 1;62(1):33-67.

19. Nolla CM. The development of permanent teeth (Doctoral dissertation, University of Michigan).
20. Moorrees CF, Fanning EA, Hunt Jr EE. Age variation of formation stages for ten permanent teeth. Journal of dental research. 1963 Nov;42(6):1490-502.
21. Demirjian A, Goldstein H, Tanner JM. AGarn SM, Lewis AB, Bonné B. Third molar formation and its development course. The Angle Orthodontist. 1962 Oct;32(4):270-9.