

INNOVATIVE 3D PLATE FIXATION TECHNIQUE FOR MANDIBULAR ANGLE FRACTURE

Dr. P. Jagadish MDS¹, Dr. S Anand Vijay MDS², Dr. Ch. Poojasree chunduru MDS^{3*},
Dr. Ganesh Koneru MDS⁴, Dr. Harshini⁵, Dr. Konda Nagasai Reddy MDS⁶

¹Consultant Department of Oral & Maxillofacial Surgery, INDIA

² Professor, Department of Oral & Maxillofacial Surgery, SIBAR Institute of Dental Sciences, INDIA

³Assistant Professor Department of Oral & Maxillofacial Surgery, SIBAR Institute of Dental Sciences, INDIA

⁴Consultant, Department of Oral & Maxillofacial Surgery, INDIA

⁵Clinical Affair specialist, Cardiac Research Department, Edwards Life sciences, USA

⁶ Senior Lecturer, Department of oral and maxillofacial surgery, SIBAR Institute of Dental sciences, INDIA

Abstract

Background: Mandibular angle fractures constitute nearly one-third of all mandibular fractures and remain challenging due to biomechanical complexity. Conventional fixation techniques, such as single or double miniplates, often compromise either stability or biological safety. Three-dimensional (3D) miniplates were introduced to enhance stability by resisting torsional and bending forces while minimizing soft tissue trauma. This study aimed to evaluate clinical, radiographic, and functional outcomes of mandibular angle fracture fixation using 3D miniplates.

Materials and Methods: Ten patients with isolated mandibular angle fractures were taken in the study. All patients underwent open reduction and internal fixation (ORIF) using a two-armed 3D miniplate via the intraoral approach. Bite force, occlusal discrepancies, and wound healing were assessed preoperatively, immediately postoperatively, and at 3-month follow-up. Data were statistically analysed using Friedman, Chi-square, and Bonferroni post-hoc tests, with significance at $p < 0.05$. **Results:** Mean bite force increased significantly from 4.28 ± 1.07 kg preoperatively to 12.08 ± 3.08 kg immediately postoperatively and 20.98 ± 1.99 kg at 3 months ($p = 0.000$). Pairwise comparison showed significant improvement between preoperative and 3-month readings ($p < 0.001$). Occlusal discrepancies were present in 80% of patients preoperatively but resolved completely postoperatively ($p = 0.000$). Wound healing scores also showed progressive

improvement, with all patients demonstrating satisfactory union and absence of infection, wound dehiscence, or plate exposure at 3 months. **Conclusion:** Fixation of mandibular angle fractures using 3D miniplates provides superior stability, early functional recovery, and excellent healing without major complications. The 3D plate system offers a biomechanically sound, minimally invasive, and reliable alternative to conventional fixation techniques.

Introduction:

Over the past two decades, there has been an alarming rise in traffic accidents, interpersonal violence, and sports-related injuries. Among the facial bones, the mandible is most frequently affected due to its prominent and exposed position. The mandibular angle, in particular, accounts for approximately 30% of all mandibular fractures.^{1,2}

The current standard of care for mandibular angle fractures is open reduction and internal fixation (ORIF) using various osteosynthesis techniques. Traditionally, fixation with a single 2.0 mm miniplate placed along the superior border has been the preferred approach, following Champy's principle, which recommends fixation along the line of tensile stress at the superior border.³ However, biomechanical analyses have demonstrated that when masticatory forces act close to the fracture line, the tension and compression zones reverse, causing the fracture to open at the inferior border.⁴ To address this instability, several authors have advocated the use of two miniplates—one at the superior and one at the inferior border—or a load-bearing plate at the lower border.^{5,6} While these methods enhance stability, they are also associated with a higher rate of biological complications, reported to be as high as 28%, thus discouraging their routine use.⁷ This has led to an ongoing debate regarding the optimal fixation method for mandibular angle fractures, as each technique carries its own advantages and limitations. In an attempt to combine the benefits of both stability and minimal complications, three-dimensional (3D) or matrix plates were introduced in 1992.⁸ These plates feature a ladder-like design positioned transversely along the mandibular angle, offering greater resistance to torsional and out-of-plane forces than conventional miniplates.⁹ The ultimate objective of any fixation technique remains the same—to achieve stable fixation, restore functional occlusion, and ensure optimal postoperative masticatory performance. Various approaches have been explored for managing mandibular angle fractures; however, the ideal technique continues to be debated. Among these, the Champy technique—utilizing transoral

placement of miniplates with mono cortical screws—remains widely practiced due to its simplicity and minimal invasiveness. Over the past two decades, titanium plates have been extensively used for rigid internal fixation. Nonetheless, concerns regarding the need for a second surgery for plate removal, along with disadvantages such as palpability and interference with growth, have stimulated interest in resorbable fixation systems. Despite these advances, the reliability of resorbable materials in fracture stabilization across various jaw sites remains controversial. Miniplate fixation with monocortical screws, particularly via an intraoral approach, continues to offer significant advantages—reduced facial scarring, shorter operative time, easier adaptation, and decreased risk of facial or inferior alveolar nerve injury—making it a preferred choice in many clinical scenarios.

Methodology

Patients with mandibular fractures confined to the interforaminal region and requiring open reduction and internal fixation (ORIF) were included. Cases with associated facial fractures were excluded. All procedures were performed under local anaesthesia. The oral cavity was prepared with povidone-iodine, and sterile drapes were applied to expose the operative site. Upper and lower arch bars were placed for occlusal stabilization. Local anaesthetic solution (2% lidocaine with 1:200,000 adrenaline) was administered. A lower vestibular incision was made along the ascending border of the mandible, extending anteriorly into the labio-buccal sulcus. A mucoperiosteal flap was elevated to expose the fracture site and the lower border of the mandible. Maxillomandibular fixation (MMF) was performed to establish occlusion, and the fracture gap was measured using cone-beam computed tomography (Figure 1). A newly designed two-armed miniplate was adapted across the fracture site, with one arm positioned on the external oblique ridge and the other on the lateral border of the mandibular ramus (Figure 2). This configuration provided three-dimensional stability by approximating the fracture segments supero inferiorly and mediolaterally. Fixation adequacy was confirmed using CBCT. Occlusion was reassessed, MMF was released, and the wound was closed in layers using 3-0 Vicryl and 3-0 Mersilk sutures. A pressure dressing was applied, and the closure time recorded. Postoperatively, all patients received a standard medication regimen and liquid diet was advised for two days followed by a soft diet for two weeks. Chlorhexidine mouth rinse was prescribed, and sutures were removed on the seventh postoperative day. Bite force and occlusion were reassessed immediately after surgery and

at 12 weeks. Patients were evaluated for pain, swelling, mouth opening, occlusion, neurosensory deficit, wound dehiscence, infection, and plate exposure. Immediate Postoperative CBCT (Figure 3) and after 3 months CBCT (Figure 4) scans were obtained to confirm reduction and plate position.

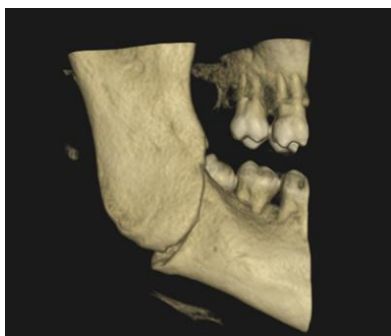


Figure1: Preoperative CBCT

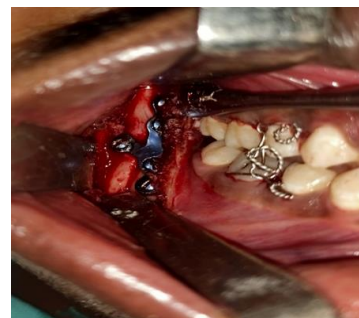

Figure 2: Plate fixation Intraorally

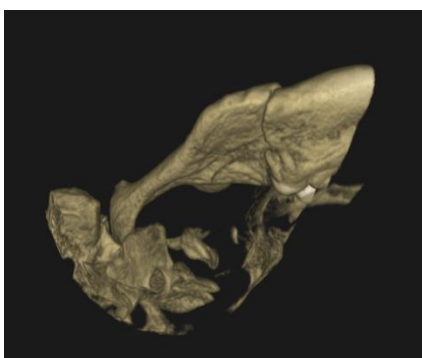


Figure 3: Immediate post op CBCT

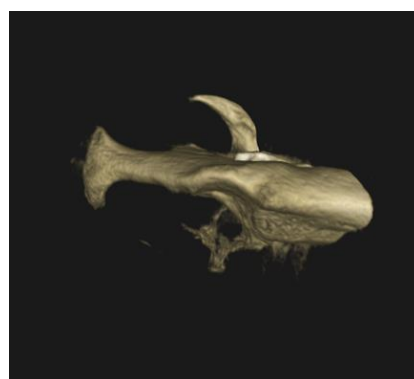


Figure 4: 3 Months post op CBCT

Statistical Analysis:

The data was compiled using Microsoft Excel and analyzed with the Statistical Package for Social Science (SPSS Version 25). The results were summarized using descriptive statistics. Kolmogorov-Smirnov tests revealed that the study data were not normally distributed, so non-parametric tests were used to compare the study parameters between the two groups, with the chi-square test and the Friedman test being used. The data in table 1 shows a statistically

significant increase in bite force was observed between the preoperative and 3-month follow-up ($P = 0.000$) reflecting progressive restoration of masticatory efficiency following fixation. No significant difference was observed between the preoperative and immediate postoperative values ($P = 0.076$) or between the immediate postoperative and 3-month assessments ($P = 0.076$).

Table 1: Pairwise comparison of bite force

Follow-up			Test statistic	P-value
Preoperative	Immediate postoperative		-1.000	0.076
	3months		-2.000	0.000*
Immediate Postoperative	3 months		-1.000	0.076

Bonferroni test post hoc test, * statistically significant

The data in Table 2 shows that there was a statistically significant increase in the mean bite force from the preoperative to postoperative periods ($p < 0.001$). The mean bite force increased from 4.28 ± 1.07 kg preoperatively to 12.08 ± 3.08 kg immediately after surgery and further improved to 20.98 ± 1.99 kg at three months postoperatively. This progressive rise in mean bite force indicates gradual functional recovery and improvement in masticatory efficiency over time following the surgical intervention.

Table 2: Mean bite force at different follow-up periods

	N	Mean	Std. Deviation	Mean Rank	
Preoperative	10	4.2800	1.07062	1.00	0.000*
Immediate postoperative	10	12.0800	3.08286	2.00	
Three months postoperative	10	20.9800	1.98875	3.00	

The data in Table3 showed that the Chi-square test showed a statistically significant association between the follow-up period and the presence of occlusal discrepancies ($p = 0.000^*$).

Preoperatively, 80% of patients exhibited occlusal discrepancies, whereas no discrepancies were observed in the immediate and three-month postoperative periods. This indicates a highly significant improvement in occlusal alignment following surgical intervention, with complete correction and stability of occlusion maintained throughout the postoperative follow-up period.

Table 3: Association between different follow-up periods for occlusal discrepancies

		Absent	Present	Total	P-value
Pre-operative	Count	2	8	10	0.000*
	% within time interval	20.0%	80.0%	100.0%	
Immediate postoperative	Count	10	0	10	
	% within time interval	100.0%	0.0%	100.0%	
3 months postoperative	Count	10	0	10	
	% within time interval	100.0%	0.0%	100.0%	

Chi-square* statistically significant

Discussion

The mandibular angle is the most frequent site of fracture, posing significant management challenges due to the absence of a universal fixation protocol. Numerous fixation devices have been developed, each claiming biomechanical superiority in terms of stability and complication reduction. Fridrich et al. (1992) analysed 1067 cases and observed that mandibular fractures predominantly occurred among males aged 20–29 years, with assaults being the leading cause. Angle fractures accounted for 26.7% of cases, followed by condylar, symphyseal, and alveolar fractures¹⁰. Choi et al., (1995) stated that due to masticatory forces, especially in the molar region, single-plate fixation often fails to counteract torsional and bending stresses, leading to displacement or gapping at the inferior border and potential infection⁵. Levy et al. (1991) suggested the addition of a second plate at the inferior border to improve stability¹¹. However, Champy et al., (1978); Silajiding et al., (2017) proposed that improper plate adaptation and screw tightening can compromise fixation stability. The Champy technique provides semi-rigid fixation by aligning plates along the ideal osteosynthesis line, neutralizing tensile stresses^{13,14}. Three-dimensional (3D) miniplates were developed to enhance Champy's concept. These plates, interconnected by crossbars, provide simultaneous stabilization of both tensile and compressive zones, resulting in better load distribution, anatomical adaptation, and reduced palpability²⁶. Comparative studies by Jain et al. (2010) demonstrated that while Champy's miniplates are simple to apply, 3D plates provide greater rigidity due to their geometric configuration¹². Vineeth et al. (2013) observed superior initial stability and lower fracture mobility with 3D plates than with conventional miniplates¹⁵. Infection remains a notable concern at the mandibular angle, often linked to third molars or instability. Ellis and Walker (1996) reported infection rates of up to 15% for Champy's plates, compared to 0–20% for 3D plates¹⁶⁻²⁰. Biomechanical investigations have shown that 3D plates resist torsional, compressive, and bending forces more effectively than conventional systems (Wittenberg et al., 1997)²². Clinical trials and meta-analyses conducted by Al-Moraissi et al., (2015); De Oliveira et al., (2018) suggest that 3D systems reduce complication rates and improve stability during functional recovery^{19,26}. Zix et al. (2007) further confirmed their suitability for simple angle fractures, emphasizing ease of adaptation and stability²³. Clinically, 3D plates provide efficient fixation with minimal gap formation and superior occlusal stability, significantly shortening operative time^{29,25,23}. The current study's findings show that postoperative

clinical manifestations such as pain and edema resolved within a reasonable time frame. Due to surgical trauma and edema, patients had inadequate mouth opening in the immediate postoperative period. However, patients' maximal mouth opening improved over time until they resumed normal mouth opening by the third post-operative month, when the opening between the upper and lower incisors easily accommodated three fingers (35-40 mm). Complications can occur as a result of a number of treatment and patient-related factors, such as patient medical conditions, surgical management, and patient compliance. These factors should be considered individually in order to provide a true relationship between post-operative complications and the plate system. The study's design bias is a limitation, as the decision to evaluate a 3D miniplate system for surgical treatment of mandibular fractures introduces selection bias.

Clinical Implications

The present study demonstrates that three-dimensional (3D) miniplate fixation for mandibular angle fractures provides excellent anatomical reduction, stable occlusion, and early return of masticatory function. The 3D configuration ensures superior resistance to torsional and bending stresses, enabling three-dimensional stabilization with minimal hardware. Clinically, this allows for improved postoperative comfort, reduced intermaxillary fixation time, and early functional rehabilitation. The intraoral approach further minimizes visible scarring and lowers the risk of facial nerve injury. These outcomes support the 3D plate as a practical alternative to conventional single or double miniplate systems in routine clinical use, especially for fractures in the mandibular angle region.

Strengths of the Study

This study highlights the effectiveness of a newly designed three-dimensional miniplate system in providing stable fixation for mandibular angle fractures. Objective assessment methods, including bite-force measurement and CBCT evaluation, ensured accurate evaluation of functional and radiological outcomes. The use of a standardized surgical protocol and consistent postoperative care minimized bias and enhanced internal validity.

Limitations

This study highlights the effectiveness of a newly designed three-dimensional miniplate system in providing stable fixation for mandibular angle fractures. Objective assessment methods, including bite-force measurement and CBCT evaluation, ensured accurate evaluation of functional and radiological outcomes. The use of a standardized surgical protocol and consistent postoperative care minimized bias and enhanced internal validity. Additionally, both early and delayed follow-up assessments allowed for a clear understanding of functional recovery over time.

Conclusion

Within the constraints of this study, the management of mandible fractures using 3D miniplates emerged in fracture reduction with a low complexity rate and an appropriate surgical procedure time. In the treatment of mandibular fractures, the use of 3-D titanium plates stabilizes the fracture segment in three dimensions. It has better interfragmentary stability than other conventional plates. These plates can be easily adapted to fit bone fragments. It necessitates less surgical exposure of the fractured site beneath the skin. The plates used in this research were 1.5mm wide and 2mm thick. As a result, the 3-D plates used in this study were discovered to be stable against traction and torsion forces, preventing plate fracture.

References

1. Olson RA, Fonseca RJ, Zeitler DL, Osbon DB. Fractures of the mandible: a review of 580 cases. *J Oral Maxillofac Surg* 1982;40 (1):23–8
2. Fridrich KL, Pena-Velasco G, Olson RA. Changing trends with mandibular fractures: a review of 1,067 cases. *J Oral Maxillofac Surg* 1992;50(6):586–9
3. Champy M, Lodde JP. Mandibular synthesis. Placement of the synthesis as a function of mandibular stress. *Rev Stomatol Chir Maxillofac* 1976;77(8):971–6.
4. Kroon H, Mathisson M, Cordey JR, Rahn BA. The use of miniplates in mandibular fractures. *J Craniomaxillofac Surg* 1991;19(5):199–204
5. Choi BH, Yoo JH, Kim KN, Kang HS. Stability testing of a two miniplate fixation technique for mandibular angle fractures. An in vitro study. *J Craniomaxillofac Surg* 1995;23(2):122–5.
6. Haug RH, Fattahi TT, Goltz M. A biomechanical evaluation of mandibular angle fracture plating techniques. *J Oral Maxillofac Surg* 2001;59(10):1199–210.

7. Ellis III E. A prospective study of 3 treatment methods for isolated fractures of the mandibular angle. *J Oral Maxillofac Surg* 2010;68(November (11)):2743–54
8. Farmand M, Dupoirieux L. The value of 3- dimensional plates in maxillofacial surgery. *Rev Stomatol Chir Maxillofac* 1992;93(6):353–7.
9. Champy, M., A. Wilk, J. H. Schnebelen : Die Behandlung von Mandibularfrakturen mittels Osteosynthese ohne intermaxill/ire Ruhigstellung nach der Technik von F. X. Michelet. *Zahn-, Mmnd-, Kieferheilk.* 63 (1975) 339
10. Kirk L Fridrich, Gustavo Pena-Velasco et al. Changing trends with mandibular fractures; A Review Of 1067 Cases. *JOMS.* 1992: 50; 586-89.
11. Levy FE, Smith RW, Odland RM, Marentette LJ. Monocortical miniplate fixation of mandibular angle fractures. *Arch Otolaryngol Head Neck Surg* 1991;117:149–154.
12. Jain MK, Manjunath KS, Bhagwan BK, Shah DK. Comparison of 3- dimensional and standard miniplate fixation in the management of mandibular fractures. *J Oral Maxillofac Surg* 2010;68: 1568–1572.
13. Champy, M.; Lodde, J.P.; Schmitt, R.; Jaeger, J.K.; Muster, D. Mandibular osteosynthesis by miniature screwed plates via a buccal approach. *J. Maxillofac. Surg.* 1978, 6, 14–21.
14. Silajiding, K.; Wusiman, P.; Yusufu, B.; Moming, A. Three dimensional versus standard miniplate fixation in the management of mandibular fractures: A meta-analysis of randomized controlled trials. *Kaohsiung J. Med. Sci.* 2017, 33, 462–472.
15. Vineeth K, Lalitha RM, Prasad K, Ranganath K, Shwetha V, Singh J. “A comparative evaluation between single noncompression titanium miniplate and three dimensional titanium miniplate in treatment of mandibular angle fracture” – a randomized prospective study. *J CranioMaxillofac Surg.* 2013;41:103–109.
16. Ellis E, Walker LR. Treatment of mandibular angle fractures using one noncompression miniplate. *J Oral Maxillofac Surg.* 1996;54:864–871
17. Bui P, Demian N, Beetar P. Infection rate in mandibular angle fractures treated with a 2.0-mm 8-hole curved strut plate. *J Oral Maxillofac Surg.* 2009;67:804–808
18. Höfer SH, Ha L, Ballon A, Sader R, Landes C. Treatment of mandibular angle fractures – linea obliqua plate versus grid plate. *J Cranio-Maxillofac Surg.* 2012;40:807–811.
19. Al-Moraissi E&g, El-Sharkawy TM, El-Ghareeb TI, Chrcanovic BR. Three-dimensional versus standard miniplate fixation in the management of mandibular angle fractures: a systematic review and meta-analysis. *Int J Oral Maxillofac Surg.* 2014;43:708–716
20. Xue AS, Koshy JC, Wolfswinkel EM, Weathers WM, Marsack KP, Hollier LH. A prospective study of strut versus miniplate for fractures of mandibular angle. *CranioMaxillofac Trauma Reconstr.* 2013;6:191–196.
21. Mohd, Y.Q.; Redy, S.; Sinha, R.; Agarwal, A.; Fatima, U.; Abidullah, M. Three-dimensional miniplate: For the management of mandibular parasymphysis fractures. *Ann. Maxillofac. Surg.* 2019, 9, 333–3339.
22. Wittenberg JM, Mukherjee DP, Smith BR, Kruse RN. Biomechanical evaluation of new fixation devices for mandibular angle fractures. *Int J Oral Maxillofac Surg* 1997;26:68–73
23. Zix J, Lieger O, Iizuka T. Use of straight and curved 3-dimensional titanium miniplates for fracture fixation at the mandibular angle. *J Oral Maxillofac Surg* 2007;65:1758–1763

24. GA M. Evaluation of 3-Dimensional Titanium Miniplates in Mandibular Fractures.
25. Pamela J Hughes. 3-D Plate versus the lag screw technique for treatment of fractures of the anterior mandible: JOMS: 2000: 58; 23.
26. De Oliveira, J.C.S.; Moura, L.B.; Menezes, J.D.S.; Gabrielli, A.C.; Pereira Filho, V.A.; Hichuli-Vieira, E. Three-dimensional strut plate for the treatment of mandibular fractures: A systematic review. *Int. J. Oral Maxillofac. Surg.* 2018, 47, 330–338.
27. Guimond C, Johnson JV, Marchena JM. Fixation of mandibular angle fractures with a 2.0-mm 3-dimensional curved angle strut plate. *J Oral Maxillofac Surg.* 2005;63: 209–214.
28. Hochuli-Vieira E, Ha TK, Pereira-Filho VA, Landes CA. Use of rectangular grid miniplates for fracture fixation at the mandibular angle. *Oral Maxillofac Surg* 2011;69(5):1436–1441.
29. Feledy J, Caterson EJ, Steger S, Stal S, Hollier L. Treatment of mandibular angle fractures with a matrix miniplate: a preliminary report. *Plast Reconstr Surg.* 2004;114:1711–1716. discussion 1717–1718.