

THE FOREIGN BODY ENIGMA: A CASE UNRAVELED IN HINDSIGHT – CASE REPORT

Dr. P Srinivas Chakravarthy MDS¹, Dr. Pooja Sree chunduruMDS^{2*}

Dr.³, Dr. P Vyshnavi³, Dr. G Mrudula⁴, Dr. Musunuri Manoj Kumar MDS FTMJF RCSEd⁵

Dr. Jyothirmai Nagisetty MDS⁶, Dr. Konda Nagasai Reddy MDS⁷

¹ Professor, Department of Oral & Maxillofacial Surgery, SIBAR Institute of Dental Sciences, INDIA

^{2,6,7} Assistant Professor, Department of Oral & Maxillofacial Surgery, SIBAR Institute of Dental Sciences,
INDIA

^{3,4} Post Graduate, Department of Oral & Maxillofacial Surgery, SIBAR Institute of Dental Sciences, INDIA

⁵ Associate Professor, Department of Oral & Maxillofacial Surgery, SIBAR Institute of Dental Sciences, INDIA

ABSTRACT

Aim: To report a rare case of a retained surgical foreign body—a syringe hub with a broken needle—in the mandibular ramus, highlighting its delayed presentation, diagnosis, and management. **Background:** Retained foreign bodies in the maxillofacial region are rare but clinically important, often resulting from trauma or surgical error. Their detection is challenging, especially in anatomically complex areas like the mandibular ramus, and delayed identification can lead to chronic symptoms. **Case Description:** A 64-year-old woman presented with pain, restricted mouth opening, and a sinus tract over the left jaw. She had undergone jaw surgery 9–10 years prior. Imaging revealed a metallic object in the mandibular ramus. Surgical exploration confirmed a retained syringe hub with a broken needle. It was successfully removed, and the patient recovered uneventfully. **Conclusion:** Retained foreign bodies can remain asymptomatic for years and present later with complications. Timely diagnosis requires clinical vigilance and imaging. **Clinical Significance:** Unexplained symptoms post-surgery should prompt suspicion of retained materials to avoid long-term complications.

INTRODUCTION

The presence of foreign bodies in the maxillofacial region is uncommon, but a significant clinical scenario may arise due to trauma, surgical interventions, or iatrogenic mishaps¹. Their detection and management can be complex, particularly when the foreign object is located near vital anatomical structures or in regions with restricted access, such as the mandibular ramus. Even more unusual is the unintentional retention of surgical components

or materials during routine follow-up without any immediate clinical suspicion². Unexplained postoperative symptoms such as localized pain, swelling, or restricted jaw movement should always prompt clinicians to consider the possibility of a retained foreign object, even in the absence of overt procedural complications. In oral and maxillofacial surgery, although foreign body entrapment is infrequent, it poses a risk of delayed diagnosis and potential complications if not identified promptly. This report details an unusual case of a retained metallic object in the mandible, discovered years after initial surgical intervention, presented with recurrent pain and sinus tract formation. This case underlines the diagnostic complexity and reinforces the importance of comprehensive evaluation and documentation.

CASE REPORT:

A 64-year-old female presented with complaints of pain, progressive restriction in mouth opening and sinus tract since 1 month. The patient presents with a dull, localized and intermittent pain in the left lower facial region, which has been progressively worsening over the past few weeks. The pain is notably exacerbated by mastication and is only partially relieved by analgesic medication. There is no radiation of pain to the ear, head, or neck regions. Medical history was non-contributory, and the patient did not have fever or any other systemic symptoms. Patient reported a history of surgery in the left posterior jaw region approximately 9–10 years ago, the details of which were vague but likely associated with the removal of multiple teeth along with their lesion in the same region, but the patient did not report any further follow-ups.

CLINICAL EXAMINATION:

On clinical examination, an extraoral sinus tract opening was observed just 1 cm anterior and 2 cm inferior to the left ear lobe, corresponding to the angle of the mandible (Figure 1). The tract appeared chronic and epithelialized, with a central opening measuring around 1 mm in diameter. The overlying skin showed mild hyperpigmentation, with no signs of active discharge or erythema noted at the time of presentation. The patient reported occasional pus discharge, particularly after wide mouth opening, which had started intermittently over the past few days. The area was tender, and there were no signs of fluctuation or induration around the sinus opening. There was no history of trauma or swelling in the area.

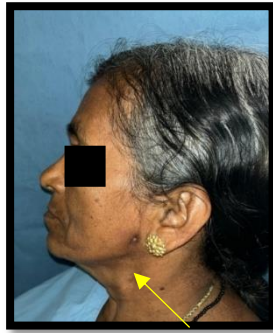

Figure 1: Clinical Photograph

On examination, the maximum interincisal opening was approximately 25 mm. No deviation or deflection of the jaw was observed on opening and closing. There was no tenderness of the temporomandibular joint (TMJ). Palpation revealed no swelling or tenderness along the masticatory muscles.

INVESTIGATIONS:

Routine preoperative investigations, including Viral markers and coagulation profile, are done.^{2,3} All the values are normal and within the range. A panoramic radiograph of the mandible showed a linear, slender radio-opaque-like structure extending from the anterior border of the ascending ramus to the posterior border in a near-horizontal plane in which outline was regular and consistent (Figure 2).

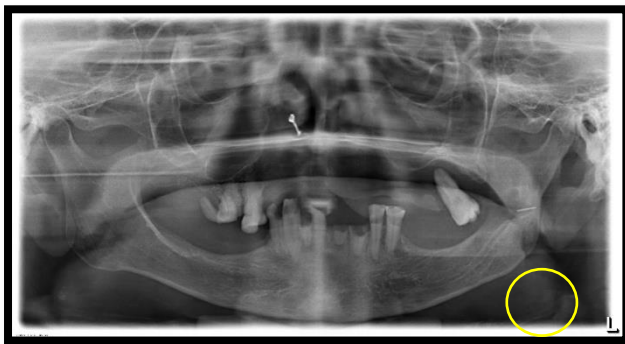

Figure 2: OPG (Preoperative Radiograph)

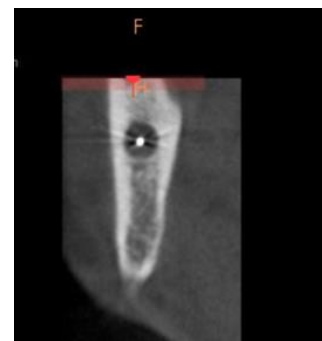

Figure 3: CBCT (sagittal view)

The diagnosis was challenging due to the patient's vague surgical history and the delayed onset of symptoms, almost a decade after the initial procedure. The nonspecific nature of pain and sinus tract further complicated clinical suspicion, necessitating imaging for definitive diagnosis. CBCT sagittal section confirmed the presence of a radiopaque structure with sharp borders measuring approximately 1.5 cm in length, surrounded by radiolucency (Figure 3). It was centrally located between the medial and lateral borders, but with no signs

of osseous perforation. There was a mild perilesional inflammatory response in adjacent soft tissue planes. No bony sequestra or new pathologies were identified. No adverse prognostic characteristics were observed. The absence of osteomyelitis, bone perforation, or systemic involvement suggested a favourable prognosis once the foreign body was surgically removed.

TREATMENT:

Initially, the patient was given broad-spectrum antibiotics, and after 5 days, the presenting symptoms eventually reduced. The patient was planned for surgical intervention. Under strict aseptic conditions, the patient is shifted to the Operating Theatre. Scrubbing is done, followed by intraoral irrigation with 7.5% Povidone Iodine solution. Local Anaesthesia of 2% Lignocaine with 1:80,000 Adrenaline concentration is given to the operating site. A crestal incision was made extending from the 36 to 38 region, and with a posterior releasing incision along the anterior border of the ramus of the mandible. A full-thickness mucoperiosteal flap was elevated, and the underlying bone was exposed (Figure 4) Upon exploration, a metallic cylindrical object, subsequently identified as the hub (Figure 5), along with its broken needle, was located within the previously operated site which was carefully dissected and freed from surrounding fibrous tissue and retrieved with artery forceps as a whole without complications. The surgical site was debrided thoroughly with betadine solution, followed by copious irrigation with normal saline. The flap was repositioned and secured with non-resorbable sutures Postoperative antibiotics and analgesics were prescribed for 3 days. The patient was monitored over a two-week postoperative period. Healing was uneventful with complete resolution of presenting symptoms, including pain and trismus. Follow-up radiographs confirmed the absence of residual foreign material.

The patient adhered well to postoperative medications and instructions, and no intolerance or complications related to therapy were noted. No adverse or unanticipated events occurred during the recovery period, and the prognosis remained favorable.

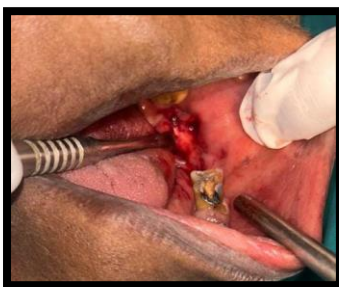


Figure 4: Intraoperative photograph



Figure 5: (syringe hub)

DISCUSSION:

Foreign body retention in the maxillofacial region is a rare yet clinically significant complication that can arise following trauma, dental procedures, or surgical interventions. The present case of a retained syringe hub in the mandibular ramus region serves as a unique and important reminder of the necessity for thorough postoperative evaluation and vigilance. Foreign bodies in the oral and maxillofacial region can include metallic fragments, broken instruments, suture needles, gauze, and syringe components. The mandible—particularly the ramus is a relatively uncommon site due to its anatomical position and limited surgical manipulation compared to other areas such as the maxillary sinus or soft tissues of the cheek and lips. Retained foreign bodies in the maxillofacial region are clinically underreported but carry significant implications. The retained foreign objects can remain dormant for years, only to present later with vague and nonspecific symptoms such as pain, swelling, or trismus.⁶ This aligns with our case, where the patient reported symptoms nearly a decade after the initial surgery. The management of such cases requires high diagnostic acumen. A meticulous clinical examination and appropriate imaging are essential for identifying embedded foreign bodies in anatomically dense regions such as the mandibular ramus. CT and MRI can aid in visualizing even small or migrated metallic fragments within soft tissue spaces like the masticator or pterygomandibular space.^{7,8} Migration of foreign bodies can complicate retrieval and lead to unexpected issues. In rare cases, broken needles have been found to migrate into deep spaces like the pterygomandibular region, likely due to tissue disruption and inflammation, causing gradual movement. These situations may present with new or shifting symptoms.^{9,10} A careful, minimally traumatic surgical approach is essential for successful retrieval, as seen in this case, where atraumatic dissection and complete removal led to rapid symptom relief. The present case highlights the strengths of thorough clinical evaluation and the utility of advanced imaging in detecting retained foreign bodies in anatomically complex regions. However, there were limitations in the management of this case. The absence of detailed surgical records from the initial procedure made it difficult to determine the exact circumstances leading to the foreign body retention. Patient perspective: The patient reported significant relief following surgery. She expressed satisfaction with the resolution of her long-standing pain and sinus tract and was relieved that no further complications were anticipated.

CONCLUSION:

This case highlights the diagnostic challenges associated with retained surgical foreign bodies in the maxillofacial region, particularly in the mandibular ramus. The delayed onset of symptoms years after surgery emphasizes the importance of considering retained materials in the differential diagnosis of unexplained postoperative complaints such as pain, trismus, or sinus tract formation. A thorough clinical evaluation combined with appropriate imaging—like panoramic radiography and CBCT—is essential for timely diagnosis. Surgical removal led to complete resolution of symptoms, reinforcing the need for prompt intervention. This case also stresses the importance of meticulous surgical technique, proper documentation, and regular follow-up to prevent such rare but significant complications.

CLINICAL SIGNIFICANCE:

Although rare, retained surgical foreign bodies in the mandibular region can lead to delayed and nonspecific symptoms. Clinicians should maintain a high index of suspicion in patients with unexplained pain, trismus, or sinus tract formation after prior surgeries. Early radiographic evaluation and intervention are crucial to prevent chronic complications and ensure complete recovery.

INFORMED CONSENT:

Written informed consent was obtained from the patient for publication of this case report and accompanying clinical images.

REFERENCES:

1. Jeyaraj P. Foreign bodies in the maxillofacial region—A review of the current literature. *J Maxillofac Oral Surg.* 2015;14(Suppl 1):S3–S11. doi:10.1007/s12663-014-0701-5
2. Chandran C, Chandran S, Nair P. Retained foreign bodies in oral and maxillofacial region: diagnostic challenges and management. *J Clin Diagn Res.* 2014;8(11):ZC118–ZC120. doi:10.7860/JCDR/2014/10349.5201
3. Agarwal AK, Sinha V, Agarwal A. Imaging of foreign bodies in the head and neck region: a pictorial review. *Insights Imaging.* 2019;10(1):1–15. doi:10.1186/s13244-019-0802-0
4. Hwang K, You SH. Surgical instruments accidentally left in the oral and maxillofacial region: review of literature and report of two cases. *J Craniofac Surg.* 2008;19(3):739–741. doi:10.1097/SCS.0b013e31816b1e8d

5. Sreelatha SV, et al. Migration of foreign body in the head and neck region: A case report and review. *J Oral Maxillofac Pathol.* 2021;25(1):146–150. doi:10.4103/jomfp.JOMFP_352_19
6. Thakur M, Sharma S, Raina A. Retained foreign body in maxillofacial region: a clinical study of 15 cases. *Indian J Otolaryngol Head Neck Surg.* 2013;65(Suppl 2):260–263. doi:10.1007/s12070-011-0363-7
7. Wong KY, King WWK, Yeung RWK, Mak KF. Surgical management of foreign bodies in the maxillofacial region: a review of the literature and report of three cases. *Br J Oral Maxillofac Surg.* 1999;37(6):429–432. doi:10.1054/bjom.1999.0175
8. Gulsen F, Sonmez G, Mutlu H, Basekim CC, Kizilkaya E. CT and MRI evaluation of a migrated broken needle in the masticator space. *Dentomaxillofac Radiol.* 2006;35(5):355–357. doi:10.1259/dmfr/28699097
9. Mittal G, Mittal S, Sharma JB, Narula V, Yadav RK. Unusual migration of a broken hypodermic needle into the pterygomandibular space: a case report. *J Clin Diagn Res.* 2014;8(6):ZD16–ZD17. doi:10.7860/JCDR/2014/8755.4441
10. Leong JL, Chan RK. Surgical retrieval of a broken needle from the pterygomandibular space. *J Laryngol Otol.* 1999;113(7):654–656.