

# "REGENERATIVE ENDODONTIC SUCCESS IN AN IMMATURE NECROTIC TOOTH WITH PREVIOUSLY INITIATED ROOT CANAL TREATMENT: A CASE REPORT"

Medikonda Asmitha Lakshmi<sup>1</sup>, Krishna Chaitanya Popuri<sup>2</sup>, Ravi Kumar Janga<sup>3</sup>,  
Ramesh Penumaka<sup>4</sup>, Dhana Prakash Gurram<sup>5</sup>, Ratna Kamal Nagelli<sup>6</sup>

<sup>1</sup>Post Postgraduate, Department of Conservative Dentistry and Endodontics, Drs. Sudha & Nageswara Rao Siddhartha Institute of Dental Sciences, India

<sup>2</sup>Professor, Department of Conservative Dentistry and Endodontics, Drs. Sudha & Nageswara Rao Siddhartha Institute of Dental Sciences, India

<sup>3</sup>Professor, Department of Conservative Dentistry and Endodontics, Drs. Sudha & Nageswara Rao Siddhartha Institute of Dental Sciences, India

<sup>4</sup> Associate Professor, Department of Conservative Dentistry and Endodontics, Drs. Sudha & Nageswara Rao Siddhartha Institute of Dental Sciences, India

<sup>5</sup> Assistant professor, Department of Conservative Dentistry and Endodontics, Drs. Sudha & Nageswara Rao Siddhartha Institute of Dental Sciences, India)

<sup>6</sup>Assistant professor, Department of Conservative Dentistry and Endodontics, Drs. Sudha & Nageswara Rao Siddhartha Institute of Dental Sciences, India)

\*Corresponding author: Medikonda Asmitha Lakshmi, Postgraduate, Department of Conservative Dentistry and Endodontics, Drs. Sudha & Nageswara Rao Siddhartha Institute of Dental Sciences, India

---

## Abstract:

Trauma to developing permanent teeth during early childhood can result in pulpal necrosis and arrest of root development. Such events lead to the formation of immature teeth characterized by thin dentinal walls, wide open apices, and incomplete root formation. These anatomical limitations make the teeth structurally weak and highly susceptible to fracture, posing challenges for long-term preservation and function. Traditional treatment modalities, such as calcium hydroxide apexification, though historically popular, offer limited success in promoting continued root development and often require multiple appointments.

In contrast, regenerative endodontic procedures (REPs) have emerged as a promising biologically based alternative, designed to reestablish vascularity, promote apical closure, and encourage maturogenesis in necrotic immature teeth. The success of REPs relies on thorough disinfection of the root canal system, the creation of a conducive environment for stem cell migration via scaffold formation (commonly through blood clot induction), and a hermetic coronal seal using biocompatible materials. Mineral trioxide aggregate (MTA) is frequently used due to its superior sealing ability and bioinductive properties.

This case report highlights a regenerative endodontic approach in a young adult with a previously traumatized anterior tooth, focusing on both biological success and esthetic preservation.

---

**Key Words:** Trauma, Immature teeth, Regenerative endodontics, MTA, platelet-rich fibrin

## **Introduction:**

Traumatic injuries to the maxillary anterior teeth are common during childhood, particularly before root development is complete. Such injuries often lead to pulpal necrosis and subsequent arrest of root formation, resulting in immature teeth characterized by thin dentinal walls, wide apical foramina, and increased susceptibility to cervical fractures. Studies indicate that up to 50% of traumatized immature teeth may develop pulpal necrosis, although only a subset present clinical signs and symptoms [1]. Arrested root development, commonly due to destruction of Hertwig's epithelial root sheath, presents significant challenges for conventional endodontic therapy.

Traditional apexification techniques induce apical barrier formation but fail to promote root maturation, often resulting in short, thin-walled roots with a higher fracture risk [2,3]. In contrast, regenerative endodontic procedures (REPs) offer a biologically based approach that supports continued root development through effective canal disinfection, scaffold formation for stem cell regeneration, and coronal sealing with biocompatible materials [4,5].

Disinfection protocols often employ irrigants such as sodium hypochlorite and ethylenediaminetetraacetic acid (EDTA), which not only disinfect but also release dentin-derived growth factors that enhance stem cell proliferation and differentiation [4,6]. Intracanal medicaments, predominantly triple antibiotic paste (TAP) or calcium hydroxide, are used to maintain antimicrobial activity between appointments [4].

Scaffold formation is commonly achieved by inducing intracanal bleeding to form a natural blood clot, which serves as a matrix for stem cells from the apical papilla (SCAP) [5,7]. To enhance regenerative outcomes, biologically enriched scaffolds such as platelet-rich plasma (PRP) or platelet-rich fibrin (PRF) are increasingly utilized due to their high concentrations of growth factors that stimulate healing and tissue formation [8].

Coronal sealing materials, typically MTA, provide an effective barrier and promote hard tissue formation [3]. However, MTA's tendency to cause tooth discoloration has led to increased use of alternative calcium silicate-based materials like Biodentine, which offers similar bioactivity with reduced esthetic compromise [9,10].

This case report describes the successful regenerative endodontic retreatment of a previously treated immature maxillary central incisor in a 23-year-old male patient with pulpal necrosis and apical periodontitis following childhood trauma. The case highlights the application of PRF as a

scaffold over the induced blood clot and discusses the importance of material selection to optimize both biological and esthetic outcomes in regenerative therapy.

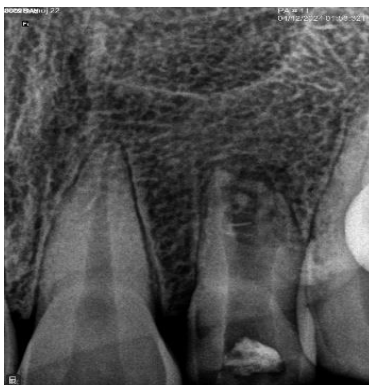## Case report

A 23-year-old male patient presented to the department of Endodontics with the chief complaint of discoloration of the maxillary left lateral incisor. He reported a history of traumatic injury to the tooth at the age of 8 years and a previously initiated root canal treatment approximately four years prior, which had not been completed. His medical history was non-contributory. Intraoral examination revealed a discoloured maxillary left lateral incisor with a coronal fracture. The tooth was asymptomatic, showed no response to cold or electric pulp testing, and was non-tender to percussion and palpation. Periodontal probing depths were within normal limits.

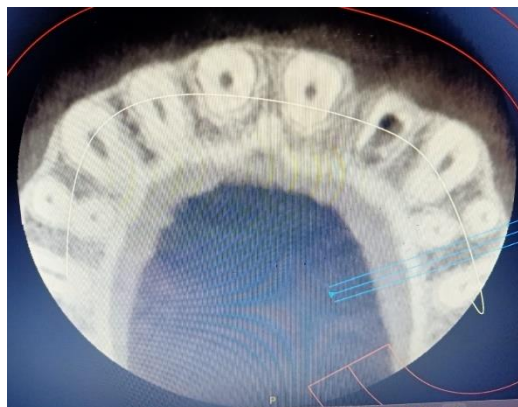
Radiographic evaluation revealed an immature tooth with a wide apical foramen ( $>1.1$  mm), thin dentinal walls, and a periapical radiolucency. There was no evidence of obturation within the canal, only a temporary restoration placed in the access cavity. Based on clinical and radiographic findings, a diagnosis of pulpal necrosis with asymptomatic apical periodontitis in an immature permanent tooth was made. Given the poor structural integrity and the wide open apex, a regenerative endodontic procedure (REP) was planned following AAE guidelines [4].

### First Visit:

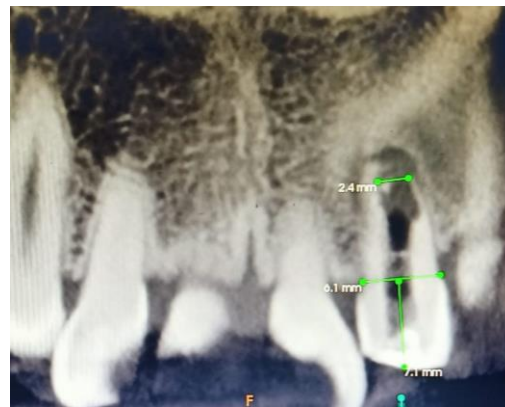After obtaining informed consent, local anesthesia was administered [4]. The tooth was isolated using a rubber dam. Upon access, no root canal filling material was found. The canal was gently irrigated with 20 mL of 2.5% sodium hypochlorite using a side-vented needle placed short of the apex, taking care to avoid mechanical instrumentation [3,4]. After thorough irrigation, a double antibiotic paste (a mixture of ciprofloxacin and metronidazole) was placed as the intracanal medicament using a lentulo spiral, and the access cavity was sealed with a non-eugenol temporary restorative material [6]. The patient was scheduled for re-evaluation after four weeks.



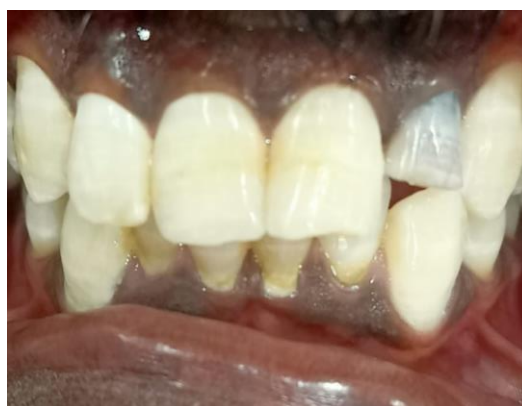**Fig 1: PREOPERATIVE INTRAORAL PERIAPICAL RADIOGRAPH OF TOOTH 22 SHOWING WIDE OPEN APEX**



**Fig 2: PREOPERATIVE CBCT -AXIAL SECTION**



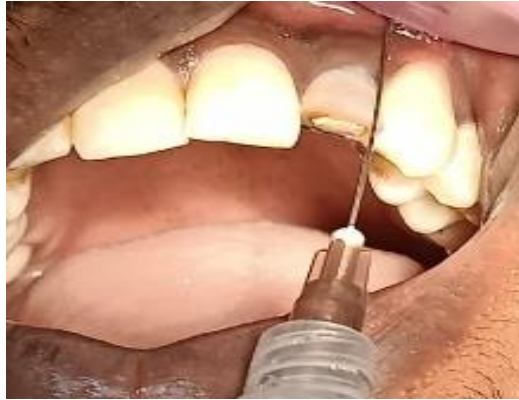**Fig 3: PREOPERATIVE CBCT-CORONAL SECTION**



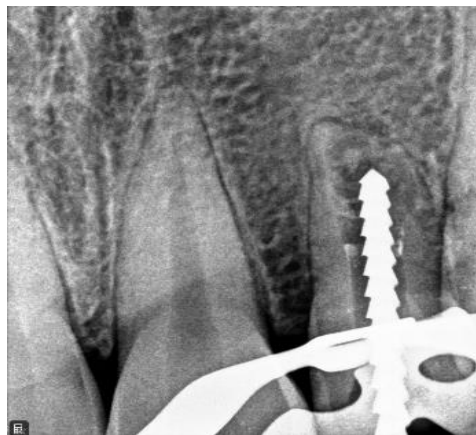
**Fig 4: PREOPERATIVE INTRAORAL PHOTOGRAPH SHOWING DISCOLOURATION OF 22**

### **Second Visit (after 4 weeks):**

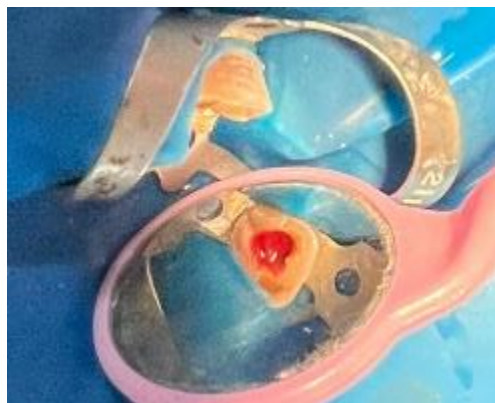
The patient was asymptomatic. The tooth was re-isolated under rubber dam, and 2% lidocaine without vasoconstrictor was administered. The double antibiotic paste was removed by irrigation with sterile saline, followed by 17% EDTA to promote the release of dentin-derived growth factors and enhance stem cell attachment [3,5]. A sterile size #25 K-file was carefully introduced 2 mm beyond the apex to irritate the periapical tissues and induce bleeding into the canal. Once bleeding reached approximately 3 mm below the cemento-enamel junction, a PRF (platelet-rich fibrin) membrane prepared from the patient's venous blood was placed over the blood clot to serve as a biological scaffold [8]. A 3–4 mm layer of mineral trioxide aggregate (MTA) was gently placed over the PRF. A moist cotton pellet was placed over the MTA, and the access cavity was sealed temporarily [7,9].



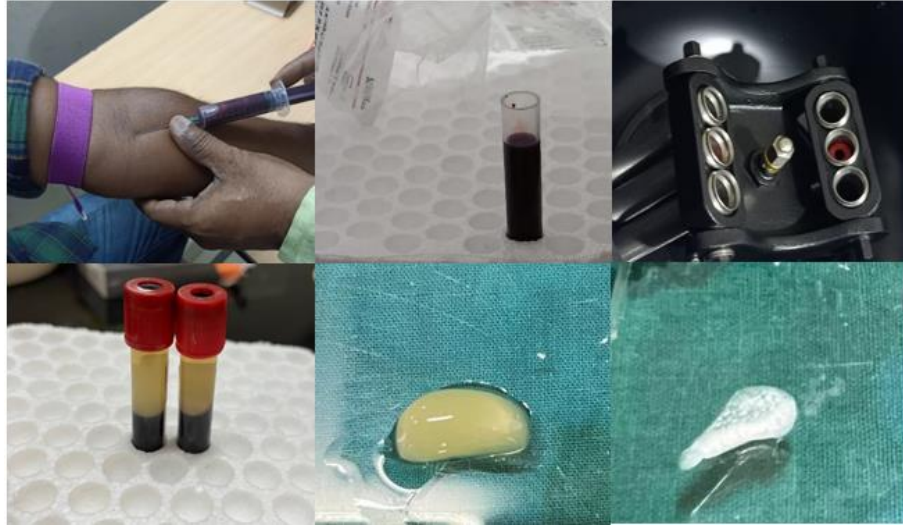
**Fig 5: ADMINISTRATION OF PLAIN LOCAL ANESTHESIA**



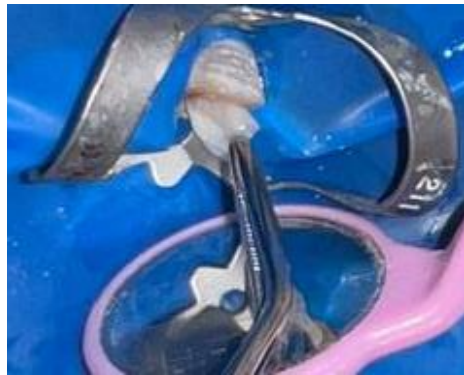**Fig 6: ACCESS OPENING & WORKING LENGTH DETERMINATION**



**Fig 7: INDUCTION OF BLEEDING INTO ROOT CANAL**



**Fig 8: PREPARATION OF PLATELET RICH FIBRIN**



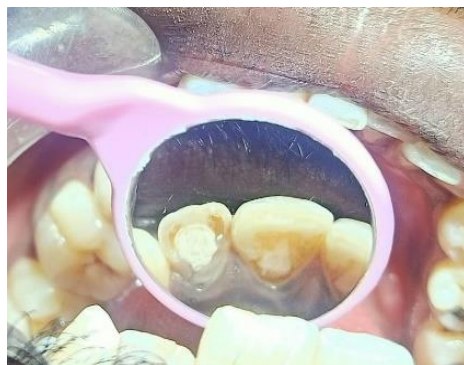**Fig 9: PLACEMENT OF PRF OVER INDUCED BLOOD CLOT**



**Fig 10: PLACEMENT OF MTA OVER PRF**



**Fig 11: POST MTA PLACEMENT**



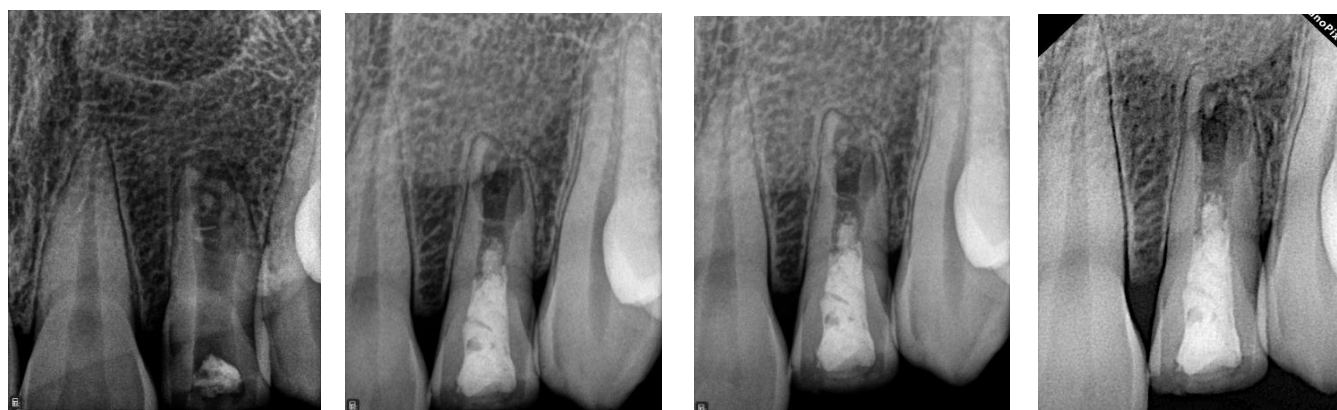
**Fig 12: TEMPORARY RESTORATION**

**Third Visit (24–48 hours later):**

After confirming the setting of the MTA, the cotton pellet was removed, and the access cavity was permanently restored with a bonded resin composite to ensure a tight coronal seal [4].

**Follow-Up:**

The patient was recalled for clinical and radiographic evaluation at 1, 3, 6 and 9 months. At the 1<sup>st</sup> month follow-up, the tooth remained asymptomatic and functional throughout. Radiographically, progressive healing of the periapical lesion, increased thickness of the dentinal walls, and signs of apical closure were observed. Continued follow-up is required to confirm the long-term success of the regenerative procedure [2,5,6].



PRE-OP

3 MONTHS

6 MONTHS

9 MONTHS

**FIG 13: FOLLOWUP**

## Discussion:

The present case highlights the successful application of a regenerative endodontic procedure (REP) in a previously initiated but incomplete root canal treatment of a traumatized immature permanent maxillary central incisor. The case emphasizes the therapeutic potential of REPs not only in managing pulpal necrosis in immature teeth but also in promoting continued root development and re-establishment of pulp vitality in adult patients [2,3].

Traditional treatment modalities such as apexification using calcium hydroxide or mineral trioxide aggregate (MTA) can achieve apical closure but do not contribute to further root elongation or thickening of dentinal walls. This structural limitation predisposes the tooth to a higher risk of cervical fracture [1,7]. In contrast, REPs aim to regenerate the pulp-dentin complex and induce maturogenesis, offering improved long-term prognosis [2,3].

According to the American Association of Endodontists (AAE) guidelines, REPs should be conducted using a triad of essential elements: disinfection of the root canal system, provision of a scaffold to support tissue ingrowth, and creation of a coronal seal to prevent bacterial recontamination [4]. In this case, a conservative irrigation protocol using 2.5% sodium hypochlorite followed by placement of double antibiotic paste (ciprofloxacin and metronidazole) was employed for canal disinfection. This combination provided effective bacterial elimination while minimizing the risk of tooth discoloration associated with minocycline in triple antibiotic paste [6].

The use of 17% EDTA at the second visit was critical to promote the release of growth factors from the dentin matrix, enhancing stem cell migration and differentiation [3,5]. Instead of relying solely on a naturally induced blood clot, platelet-rich fibrin (PRF) was utilized as a biologically enriched scaffold. PRF has shown promising results in regenerative procedures due to its sustained release of growth factors such as PDGF, TGF- $\beta$ , and VEGF, which enhance angiogenesis and tissue regeneration [8].

MTA was selected as the coronal sealing material due to its excellent biocompatibility and capacity to induce hard tissue formation [7]. However, given the esthetic considerations in anterior teeth, it is important to note that materials such as Biodentine may offer similar regenerative properties with reduced risk of discoloration [9,10]. In this case, MTA use was successful without visible discoloration, possibly due to its placement over PRF and below the CEJ.

A remarkable clinical outcome was observed at the 6-month follow-up, with a positive response to cold testing indicating possible revascularization and reinnervation of the pulp space. Radiographic findings over subsequent follow-up intervals showed continued root maturation, thickening of dentinal walls, and resolution of the periapical lesion. These findings align with existing literature that supports the potential for functional recovery and structural repair in necrotic immature teeth managed with REPs [2,5,6].

Although the exact histological nature of the tissue formed within the canal after REP remains a subject of debate, studies have demonstrated the formation of tissues resembling cementum, bone, and fibrous connective tissue [2,3]. Regardless of the exact tissue type, clinical success is often defined by the elimination of symptoms, resolution of apical pathology, and evidence of root development—outcomes all achieved in the present case [4,6].

This case also underscores the feasibility of REPs in adult patients, even several years after trauma and initial treatment, as long as residual stem cell viability and adequate apical diameter are present [5,6]. The success of this case supports the inclusion of REPs as a valid retreatment option for previously treated immature permanent teeth with persistent periapical pathology.

### Conclusion:

Regenerative endodontic procedures provide an effective treatment option for non-vital immature permanent teeth with open apices and thin dentinal walls. This case highlights the successful retreatment of an incompletely treated central incisor using AAE-recommended protocols. Disinfection with double antibiotic paste, use of PRF as a scaffold, and sealing with biocompatible materials led to healing, continued root maturation, and recovery of pulp sensibility. REPs can offer favorable clinical and esthetic outcomes, even in previously treated teeth, supporting their growing role in contemporary endodontics

### References:

1. Andreasen JO, Farik B, Munksgaard EC. 2002. Long-term calcium hydroxide as a root canal dressing may increase risk of root fracture. *Dent Traumatol.* 18(3):134–137. <https://doi.org/10.1034/j.1600-9657.2002.00020.x>
2. Trope M. 2008. Regenerative potential of dental pulp. *J Endod.* 34(7 Suppl):S13–S17. <https://doi.org/10.1016/j.joen.2008.02.028>
3. Hargreaves KM, Diogenes A, Teixeira FB. 2013. Treatment options: Biological basis of regenerative endodontic procedures. *J Endod.* 39(3 Suppl):S30–S43. <https://doi.org/10.1016/j.joen.2012.11.025>
4. American Association of Endodontists. 2018. Clinical considerations for a regenerative procedure. AAE Consensus Conference Recommended Guidelines. [accessed 2025 May 29]. [https://www.aae.org/specialty/wp-content/uploads/sites/2/2018/06/ConsiderationsForRegEndo\\_AsOfApril2018.pdf](https://www.aae.org/specialty/wp-content/uploads/sites/2/2018/06/ConsiderationsForRegEndo_AsOfApril2018.pdf)
5. Banchs F, Trope M. 2004. Revascularization of immature permanent teeth with apical periodontitis: new treatment protocol? *J Endod.* 30(4):196–200. <https://doi.org/10.1097/00004770-200404000-00002>
6. Jeeruphan T, Jantarat J, Yanpiset K, Suwannapan L, Khewsawai P, Hargreaves KM. 2012. Survival of immature teeth following regenerative endodontic procedures: A comparative study with a traditional apexification technique. *J Endod.* 38(10):1330–1336. <https://doi.org/10.1016/j.joen.2012.06.028>
7. Torabinejad M, Parirokh M. 2010. Mineral trioxide aggregate: A comprehensive literature review – Part II: Leakage and biocompatibility investigations. *J Endod.* 36(2):190–202. <https://doi.org/10.1016/j.joen.2009.09.010>

- 8.** Ranganathan LK, Rao S, Shankar T, Prabhakar M, Mahadev S, Setty S. 2020. Comparative evaluation of platelet-rich plasma and platelet-rich fibrin as scaffold in regenerative endodontics: An in vitro study. *J Conserv Dent.* 23(4):402–407. [https://doi.org/10.4103/JCD.JCD\\_431\\_19](https://doi.org/10.4103/JCD.JCD_431_19)
- 9.** Camilleri J. 2014. Color stability of white mineral trioxide aggregate in contact with hypochlorite solution. *J Endod.* 40(3):436–440. <https://doi.org/10.1016/j.joen.2013.11.005>
- 10.** Giraud T, Jeanneau C, Bergmann M, Laurent P, About I. 2020. Tricalcium silicate-based material modulates pulp healing and dentin bridge formation. *J Endod.* 46(4):493–501. <https://doi.org/10.1016/j.joen.2019.12.008>