

Clinical Observations on the Correlation Between *Enterobius vermicularis* and Appendicitis Occurrence

¹Dr. Alexei Romanov

Department of Medical Sciences, Imperial College London, United Kingdom

²Dr. Yasmin El-Sayed

Faculty of Medicine, Cairo University, Cairo, Egypt

³Dr. Martina Kühn

Department of Medicine, Ludwig Maximilian University of Munich, Germany

Abstract:

Objective: The purpose of this research work is to assess the painful and swollen appendix because of EV (*Enterovirus Vermicularis*).

Study Design: The removal of appendix from every patient carried out and histopathological assessment of the samples conducted.

Study Setting: The collection of the samples carried out from the patients who got admission in Allied Hospital Faisalabad.

Study Subjects: The examination of twelve hundred and fifty-three appendices carried out to put light on the available association between the prevalence of *enterobius vermicularis* & the foundation of the inflammation. The evaluation of the painful and swollen appendix carried out because of *enterobius vermicularis*.

Results: The findings of this case work showed that only nine patients out of twelve hundred and fifty-three patients (0.70%) were available with the infections of *enterobius vermicularis*, containing five female patients and four male patients from eight to thirty-six year of age. In the time of surgery of two patients from female gender, revealing of cysts of ovaries carried out at the same time.

Conclusion: The availability and presence of the *enterobius vermicularis* in the painful and swollen appendix can be reason of different sign and symptoms and appendicitis inflammation.

Keywords: Appendicitis, Vermicular, *Enterobius*, Foundation, Gender, Infections, Embrocated Egg, Swollen, Large Intestines.

Corresponding author:

Dr. Alexei Romanov

Department of Medical Sciences, Imperial College London, United Kingdom

INTRODUCTION:

The most common parasite of the intestines of human beings with a wide range of distribution of geographical regions particularly in the setting of primary heal care regardless of race, social and economic condition and circumstances of different culture id enterobius vermicularis [1]. More than two hundred million peoples of the world have infections. The pinworm of male is from two to five-millimeter-long and females have reached a length of eight to thirteen millimeters. Upon intake of the embrocated egg, the larva of first stage hatches inside the duodenum. The progressive stage of the larva molt to times before touching the adulthood in jejunum & upper ileum [2].

This current research work showed that although enterobiasis of the intestines in very frequent among children but the patients of enterobius vermicularis appeared in swollen and painful were available in the patients especially in the age of more than fourteen years and it was very commonly appeared in the patients suffering from acute appendicitis. Mostly the adult worms dwell in the cecum as well as the linked portions with small & large intestines. The worms of females when completely gravid, move down to the tract of intestines to pass out from anal opening & they usually deposit their eggs inside. The medical signs are mostly perianal. Perianal as well as the irritation in vagina is because of the worm of gravid female. The

most natural and suitable habitat of the pinworm is the area inside and adjacent to large intestines, but it can move and make its habitat in any organ [3]. In this case work, we evaluated the nine patients of appendicitis because of enterobius vermicularis.

METHODOLOGY:

The removal of one thousand two hundred and fifty-three appendices carried out in five-year period from 2014 to 2018 in the surgical department of Allied Hospital Faisalabad. We sent all these samples to the laboratory of pathology to know about the probable association among the prevalence of the E. vermicularis & the foundation of the inflammation of the painful & swollen appendix. The cutting of the specimens carried out in thickness marked with haematoxinilin eosin & microscope was in use of the examination of the samples. SPSS V. 15 was in use for the statistical analysis of the collected information and ethical committee of the hospital gave the permission to conduct this research work.

RESULTS:

In nine patients out of one thousand two hundred and fifty-three patients of painful and swollen appendix, E. vermicularis was the confirm diagnosis in assessment of pathology of histological ingredient. The summary of the features of all the patients are available in Table-1.

Table-I : characteristics of patients with vermiform appendix

Case	Sex	Age (Years)	Perioperative Diagnosis	Operative Diagnosis	Surgical Pathology Report
i	Female	19.0	A.App	Appendix normal at gross pathology. Ovarian cyst	Vermiform appendix with E.v. Ovarian luteal body cyst
ii	Male	8.0	A.App	Acute suppurative appendicitis with perforation	A.App with periappendicitis and E.v.
iii	Female	36.0	A.App	A.App	Early A.App infection of E.v
iv	Female	35.0	A.App	A.App ovarian cyst	Vermiform appendix with E.v infection. Ovarian luteal body cyst
v	Female	14.0	A.App	A.App	Unremarkable appendix with body and ova. of E.v
vi	Male	11.0	A.App	A.App	Appendix with dilated lumen containing E.v
vii	Female	34.0	A.App	A.App	A.App with periappendicitis and E.v
viii	Male	18.0	A.App	A.App	A.App with periappendicitis and E.v
ix	Male	13.0	A.App	A.App	Vermiform appendix with E.v

A.App : Acute Appendicitis

E. vermicularis localization in the complication of appendicitis are clearly visible in Figures-1 and Figure-2.

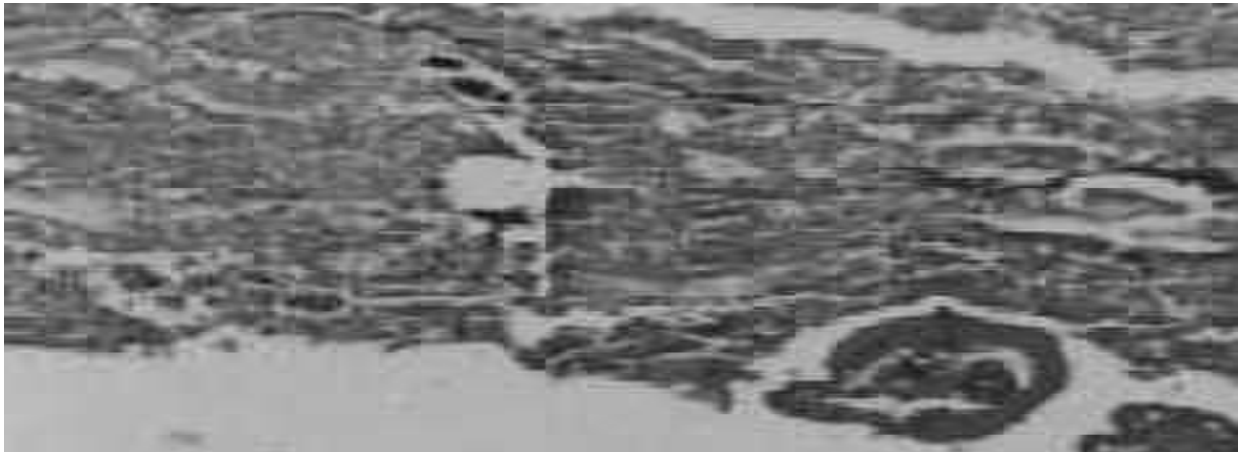


Figure 1: Section of vermiform appendix with *E. vermicularis*. H & E staining (100 x)

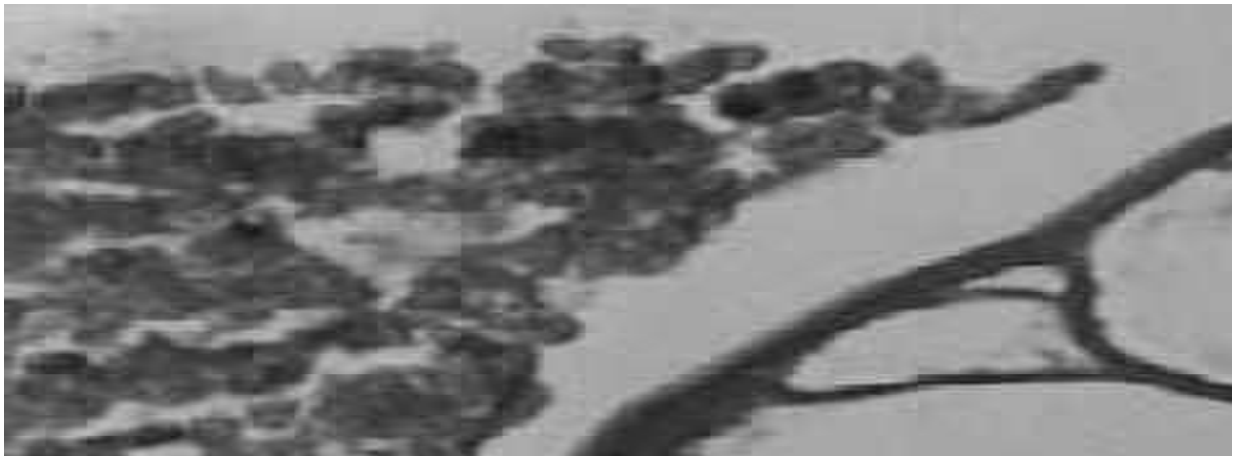


Figure 2 : Cross section of *E. vermicularis*. H & E staining (400 x)

DISCUSSION:

Majority of the patients with extra localization in intestines of the enterobius vermicularis are available in reports, incursion of the cavity of peritoneal from the reproductive system of females in the creation of the blisters or granuloma surrounding the eggs or the worms [4, 5, 6]. They have no medical importance but it is supposition that they are accountable for the complication of the pelvic peritonitis [7]. Corea in his research work reported the perianal abscess [8] and extra pinworm abscess of intestines of intestines has an association with the complication of hernia as reported by the research work conducted by Tomieporth [9]. Adult worms of the parasite of enterobius vermicularis ova were available in the smears of vagina [10-12], in urine [13], and even in macerated embryo of the human beings [14].

There is also report of the patients of nocturnal, dysuria, enuresis [15], epididymitis [16], central

hemorrhagic chorioretinopathy particularly eye of left side [17] because of enterobius vermicularis. The formation of the granuloma around the egg of pinworm inside the liver was in the conclusion of the research works of Little in 1973 [18], Dalyand Baker [19] Mondov & Gnepp [20]. An adult pinworm with female gender was available on thoracotomy for a non-calcified nodule of pulmonary nodule have an access to the cavity of peritoneal from region of necrotic in an adeno-carcinoma of the intestines as elaborated by the Beaver [21].

Maraghi also concluded in his research work a patient of pinworm in the fluid of the cerebrospinal [22]. Chandrasoma & Mendis have presented in their research work the proofs that this is ability of the pinworms to enter through the intact wall of the bowel [23]. Incursion of the swollen and painful appendix may have the expectations to be very frequent prevalence which it is truly but there was no proof of

the association between the incursion & painful and swollen appendix [24, 25]. The histological results of different works on the intramural parasitic worms are very clear and well-recognized [26, 27]. Budd & Armstrong checked the one thousand four hundred and nineteen appendicitis separated from the patients suffering from painful and swollen appendix and one hundred and ten patients with other surgical methods, they also identified enterobius vermicularis in 2.70% patients suffering from clinical appendicitis [28].

This current research work showed that although enterobiasis of the intestines is very frequent among children but the patients of enterobius vermicularis appeared in swollen and painful were available in the patients especially in the age of more than fourteen years and it was very commonly appeared in the patients suffering from acute appendicitis. While performing the surgery of 2 female patients, we revealed the cyst of ovaries in two female patients & in the meanwhile, the removal of the appendices also carried out. The identification with the help of histopathological methods verified the form of the appendix due to enterobius vermicularis & leuteal cyst of ovaries in both of the patients.

Mastuoke concluded in his research work with assessment carried out with the help of histology, he checked a routine appendix & the medical identification was the chronic appendicitis, he was able to find the pinworm in the lumen of that very appendix [29]. Some other authors in their research works discovered the presence of pinworms in lower than one percent of the evaluated appendices [30, 31]. Al Rabia in his research work concluded that the patients which were available with the confirm evidences of the disease with the utilization of histology due to enterobius vermicularis among two hundred and one surgical removals of the painful and swollen appendix [32].

A more recent research work evaluating the two thousand two hundred and sixty-seven painful and swollen appendix displayed that there was a very high important disparity available in the prevalence of the enterobius vermicularis in the cases of the normal appendices & appendicitis with inflammation which can show that the availability of the enterobius vermicularis in the appendix can provide the symptoms of acute cases of appendicitis [24].

CONCLUSION:

The observations based on the medical as well as histopathological findings shows that *E. vermicularis* can be the reason of swollen and painful appendix. *E. vermicularis* in the complication of painful and swollen appendix should be under consideration in the

period of complete course of any other chronic pelvic diseases with inflammation particularly in patients of female gender.

REFERENCES:

1. Mattia AR. Perianal mass and recurrent cellulitis due to *Enterobius vermicularis*. *Am J Trop Med Hyg*, 1992; 47:811-5.
2. Mortensen NJ, Thomson JP. Perianal abscess due to *Enterobius vermicularis*. Report of 3 cases. *Dis Colon Rectum* 1984; 27:677-8.
3. Vafai M, Mohit P. Granuloma of the anal canal due to *Enterobius vermicularis*, Report of a case. *Dis Colon Rectum* 1983; 26:349-50.
4. Pearson RD, Irons RP Sr, Iron RP Jr. Chronic pelvic peritonitis due to pinworm, *Enterobius vermicularis*. *J Am Med Assoc* 1981; 245:1340-41.
5. Brown HW, Neva FA. Basic clinical parasitology. 6th ed. Appleton century – crofts. New York 1994, pp. 128-32.
6. Corea RT. *Enterobius Vermicularis* in an ectopic site perianal abscess. *Ceylon Med J*, 1983; 28:255-6.
7. Russell LJ. The pinworm, *Enterobius vermicularis*. *Prim Care* 1991; 18:13-24.
8. Markell EK, Voge M, John DT. Medical parasitology 6th ed. Saunders Company. London 1999, pp. 220-2.
9. Tomieporth NG, Disko P, Brandis A, Barutzki, D. Ectopic enterobiasis. A case report and review. *J. Infect*, 1992, 24,87-90
10. Demirezen S, Karayazgan Y. Eggs of *Enterobius vermicularis* in vaginal smears. *Microbial. Bull*, 1986; 20:290-4.
11. Mckay T. *Enterobius vermicularis* infection causing endometritis and persistent vaginal discharge in three siblings. *N Z Med J*, 1989; 102:56.
12. Deshpande AD. *Enterobius vermicularis* live adult worms in the high vagina. *Postgrad Med J* 1992; 68:690-91.
13. Adungo NI, Ondigo SO, Pamba HO. Observation of *Enterobius vermicularis* ova in urine, 3 cases reports. *East Afr Med J* 1989; 63:676-8.
14. Mendoza B, Jorda M, Rafel E, Simon A, Andrada E. Invasion of human embryo by *Enterobius vermicularis*. *Arch Pathol Lab Med* 1987; 111:761-2.
15. Eterba JM. Appendiceal enterobiasis: its incidence and relationships to appendicitis. *Folia Parasitol (praha)*, 1984; 31:311-8.
16. Gokalp A, Gultkin EY, Kirisci MF, Ozdamar S. Relation between *Enterobius vermicularis* infestation and dysuria, nocturia, enuresis.

- Nocturia and bacteriuria in primary school girl. *Indian Pediatric* 1991; 28:948-50.
17. Colins DC. Study of 50000 specimens of the human appendix. *Surg Gynecol Obstet* 1955; 101:435-7.
 18. Kollias, G., Kyriakopoulos, M., Tiniakos, G. Epididymitis from *Enterobius vermicularis*. Case Report. *J Urol* 1992; 147:1114-6.
 19. Schmidt D, Cony T. A case from practice. Eosinophilia in *Enterobius vermicularis* infection. Central haemorrhagic chorioretinopathy of the left eye. *Schewiz Rundsch Med Prak* 1990; 79:1308-10.
 20. Little MD, Guello GJ, D' Alessandro A. Granuloma of the liver due to *Enterobius vermicularis*. *Am J Trop Med Hyg* 1973; 22:567-9.
 21. Al Rabiah F, Halim MA, Ellis ME, Abdulkareem A. *Enterobius vermicularis* and acute appendicitis. *Saudi Med J* 1996; 17:799-802.
 22. Daly JJ, Baker GF. Pinworm granuloma of the liver. *Am J Trop Med Hyg* 1984; 33:62-4.
 23. Mondou EN, Gnepp DR. Hepatic granuloma resulting from *Enterobius vermicularis*. *Am J Clin Pathol*, 1989;91:97-100.
 24. Beaver PC, Kriz JJ, Lav TJ. Pulmonary nodule caused by *Enterobius vermicularis*. *Am J Trop Med Hyg* 1973; 22:711-3.
 25. Maraghi S. *Enterobius vermicularis* in cerebrospinal fluid. *Iranian Biomed J* 1997; 1:49-51.
 26. Chandrasoma PT, Mendis KN. *Enterobius vermicularis* in ectopic site. *Am J Trop Med Hyg* 1977; 26:644-9.
 27. Wiebe K. Appendicitis and *Enterobius vermicularis*. *Scand J Gastroenterol* 1991; 26:336-8.
 28. Baharkaran CS, Devi ES, Rao KV. *Enterobius vermicularis* of veriform appendix. *J India Med Assoc*, 1975;64:334-46.
 29. Mogensen, K. *Enterobius vermicularis* and acute appendicitis. *Acta Chir Scand* 1985; 151:705-7.
 30. Richmond HG, Guthrie W. *Enterobius vermicularis* of veriform appendix. *J Pathol Bacteriol* 1964; 87: 415-20.
 31. Budd JS, Armstrong C. Role of *Enterobius vermicularis* in etiology of appendicitis. *Br J Surg* 1987; 74:748-9.
 32. Masuoka Y. On the pathology of worm infection of veriform appendix. *J Pathol Bacteriol* 1916; 21:221-47.